B-line to Feline CHF:

Point of care ultrasound to diagnose feline congestive heart failure in the emergency room

Andrew Taylor, MS, DVM, DACVECC

MedVet Columbus

February 2022

MEDVET
Leading Specialty Healthcare for Pets

Andrew Taylor, MS, DVM, DACVECC



- Williams College – BA 2007
- UMass, Amherst – MA
- THE Ohio State University – DVM
- ER DVM in Cleveland
- Tufts – Internship
- **University of Wisonsin, Madison – ECC Residency 2021**

Tully – est. 2007!

MedVet

Outline

- Case introduction
- POCUS
- Literature review
- Case summary

Presentation to the ER



8yr MC DSH



Presented to ER for intermittent cough, lethargy, anorexia, hiding



RR: 60 brpm, increased effort, crackles ausculted

History

Presented to referral partner 2 years ago

CXR - diffuse bronchial pattern

Dx: asthma

Treated with prednisolone (0.5mg/kg PO q24h)

Clinical signs have been well controlled - owners noticed increase in respiratory rate approximately 2 weeks ago, but still eating until today

Initial stabilization



- Sedation: butorphanol 0.3mg/kg IM
- Oxygen
- Too unstable for CXR

Ddx: Feline Lower Airway Disease

- **Pulmonary Edema**
  - **Cardiogenic - CHF**
  - Non-cardiogenic – ARDS, upper airway obstruction, electrocution/drowning, seizures (rare)
- Pulmonary contusions – secondary to trauma
- Neoplasia
- Pneumonia – rare

WET lung

- Asthma – 1% - 5% feline population affected
  - secondary infection *uncommon*

DRY lung

Haskins, 1999

MedVet

POCUS
Point Of Care Ultrasound

MedVet
Leading Specialty Healthcare for Pets

POCUS

- Non-invasive
- Requires minimal patient restraint
- Performed simultaneously with other interventions
- Performed serially for monitoring
- Radiation sparing
- Inexpensive

MEDVET

POCUS - synonyms

- FLASH
- FAST Scan
- VET BLUE

Probes

Curvilinear Probe
(depth)



Linear Probe
(detail)



https://www.sonosite.com/products/transducers

MEDVET

Thoracic exam



Heart

Pericardial effusion

LV size/function

LA:Ao

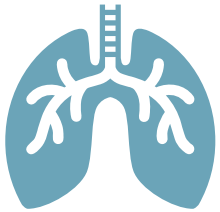

Lungs

Wet vs. Dry



Pleural space

Effusion



Cardiac Exam

Curvilinear Probe

MEDVET
Leading Specialty Healthcare for Pets

Positioning

LEFT of image

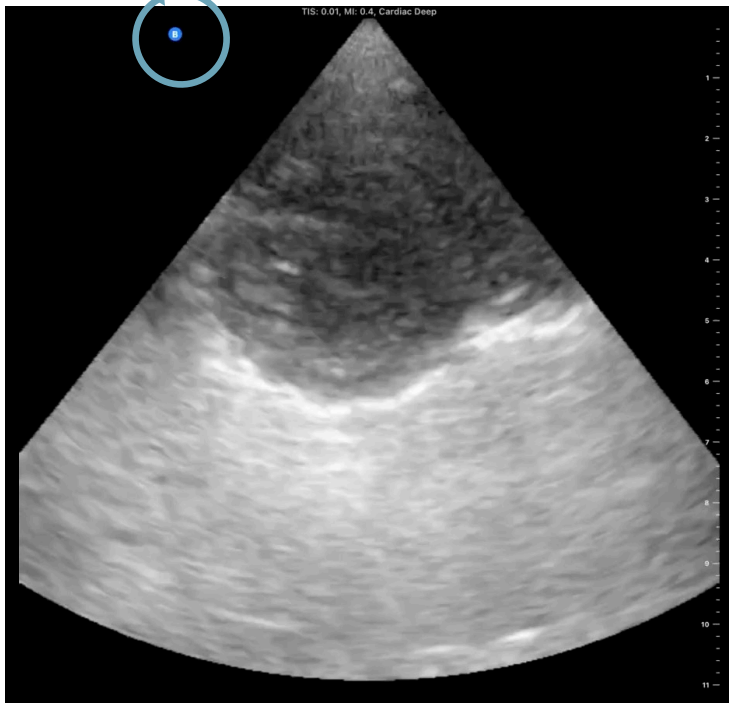

BACK of dog/cat



https://www.sonosite.com/products/transducers

MEDVET

Evaluate the LV

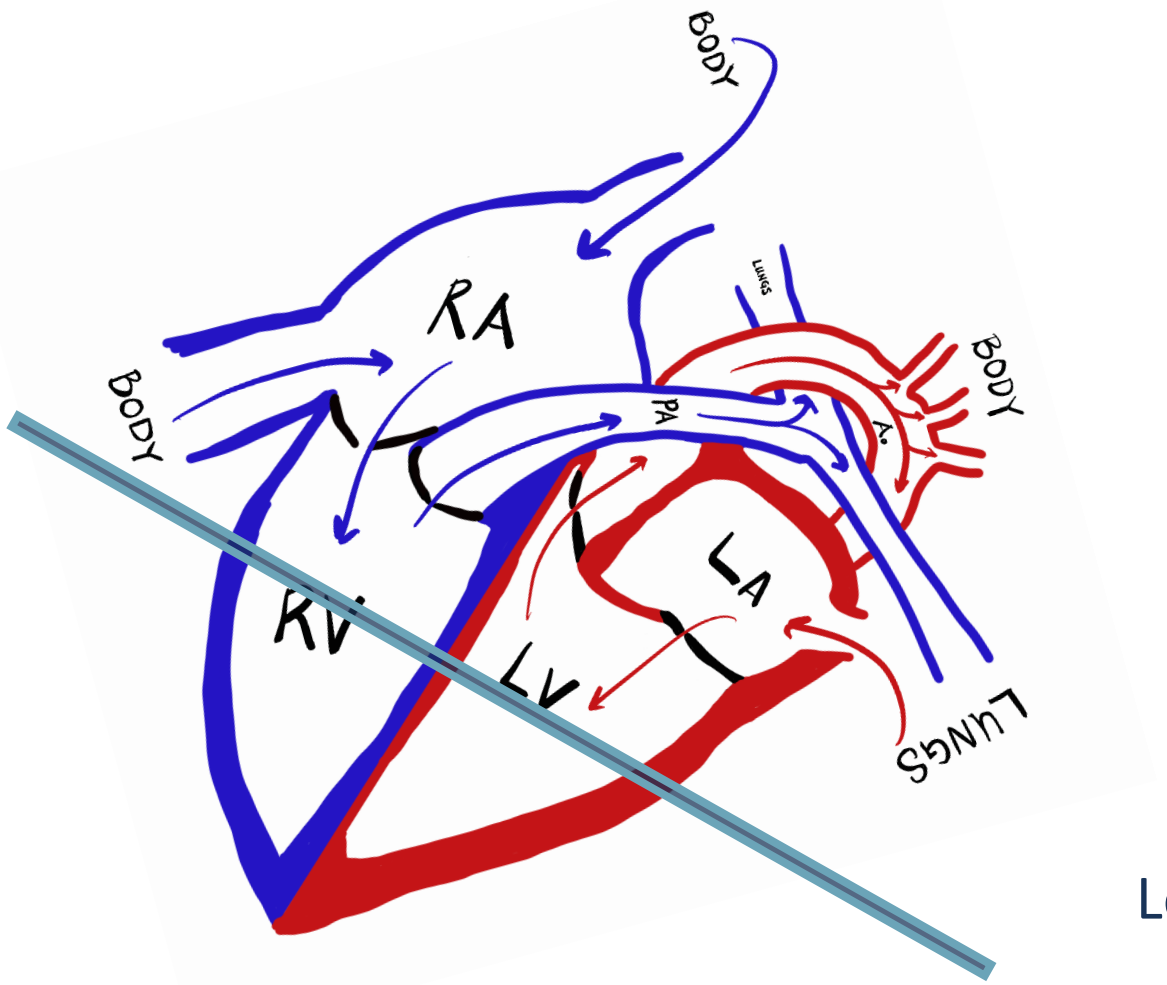

Right – short-axis parasternal view
"Shroom View"

- Evaluate filling
- Evaluate contractility



MEDVET

Cine of LV – short axis



Hand position to evaluate LA:Ao

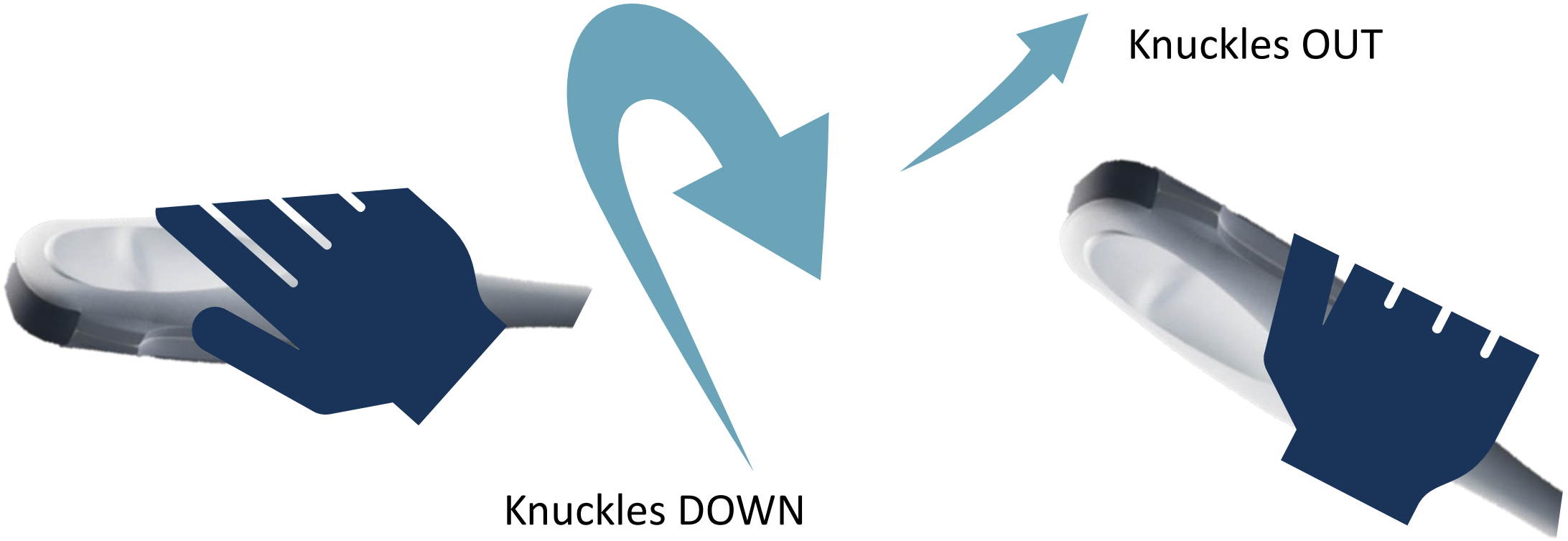

LA:Ao: normal ratio = < 2

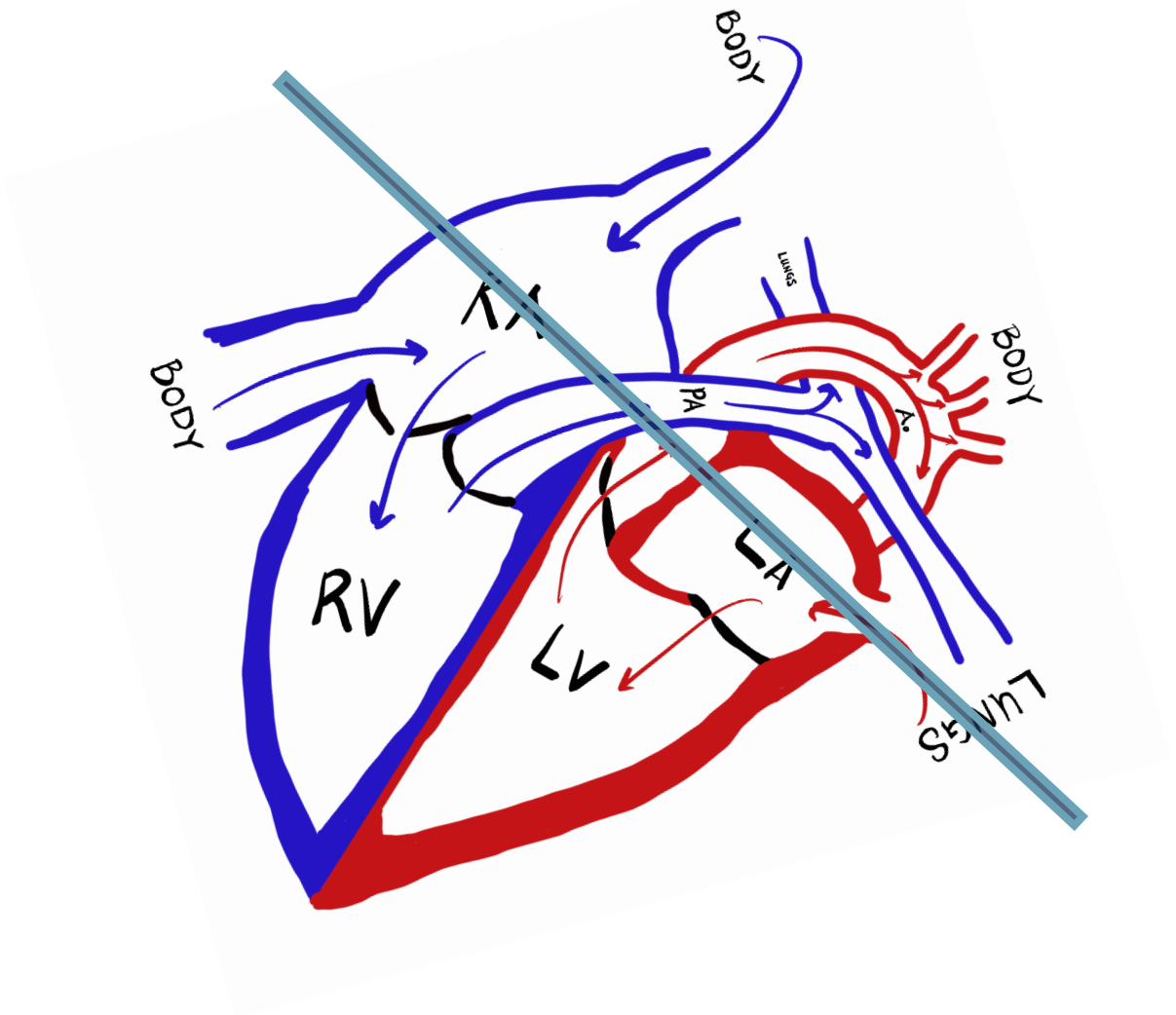



MEDVET

Cine of LA:Ao



LA:Ao > 2 → consistent with *chronic* LA overload

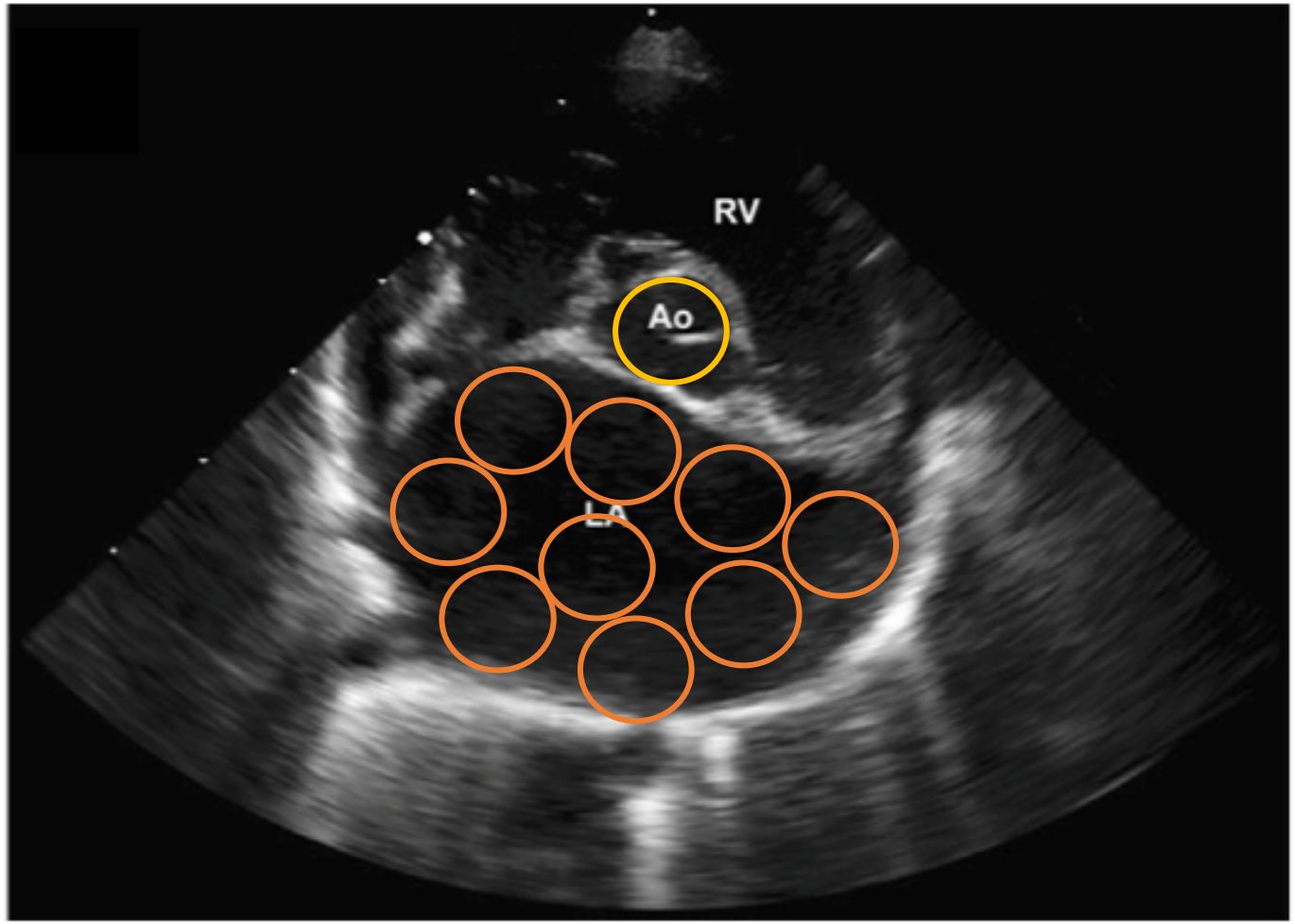

DeFrancesco, 2013

MEDVET





Pulmonary Exam

Curvilinear or Linear Probe

MEDVET
Leading Specialty Healthcare for Pets

Vet BLUE protocol



Scan both sides of the patient's chest

Ward, 2018.

MEDVET

Pulmonary Terms

- **P-P Line / PPI / Glide Sign:**
  - **To-and-fro sliding** of the lung in real time against the pleural wall
  - Pulmonary – pleural interface during respiration
  - Indicates NORMAL position of lung against the thoracic wall

- **A – Lines:**
  - Repeated parallel **horizontal** lines from the P-P line *through* the far field
  - Represent **DRY** lung
  - Formed by AIR reverberation artifact within the pulmonary parenchyma

- **B – Lines:**
  - **Vertical** streaks that oscillate with respiration and obliterate A-lines through the far-field
  - Represent **WET** lung (blood, pus, water)
  - Formed by the variation in acoustic impedance at the air-fluid interface

Lungs – Curvilinear Probe

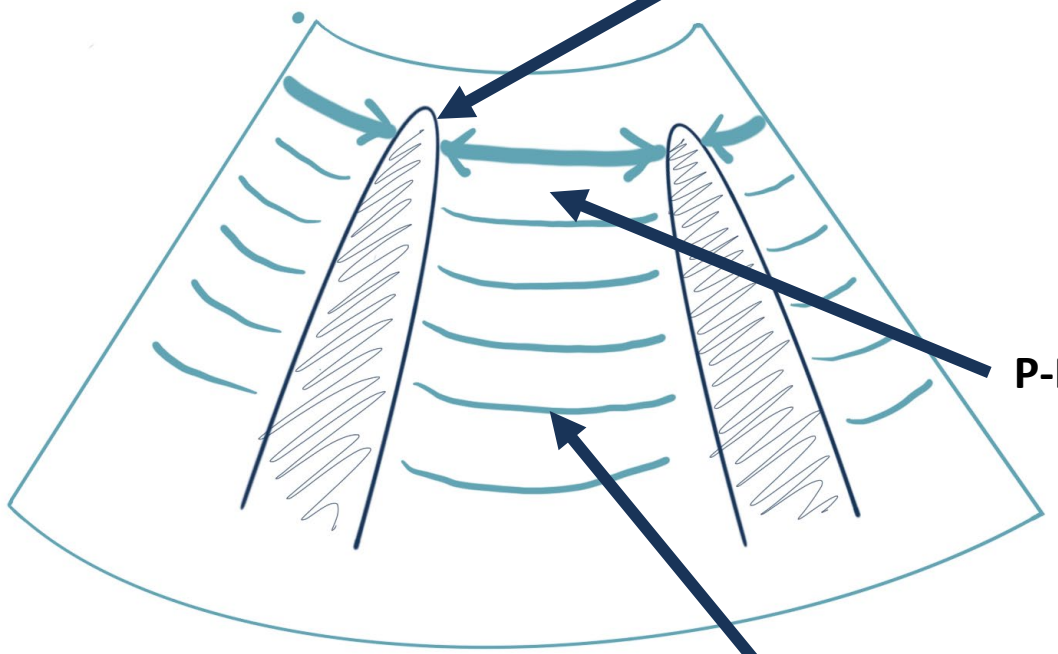

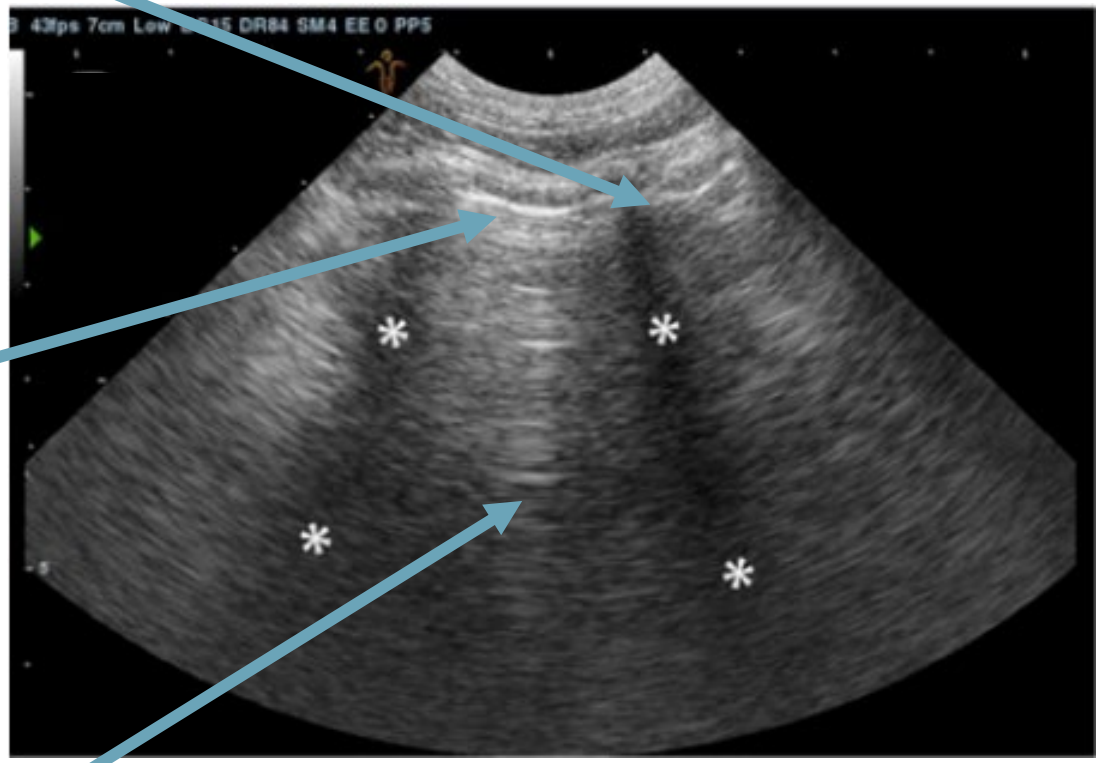

* = shadowing from ribs

P-P LINE

A-lines: DRY lung

Ward, 2018

MedVet

Lungs – Curvilinear Probe

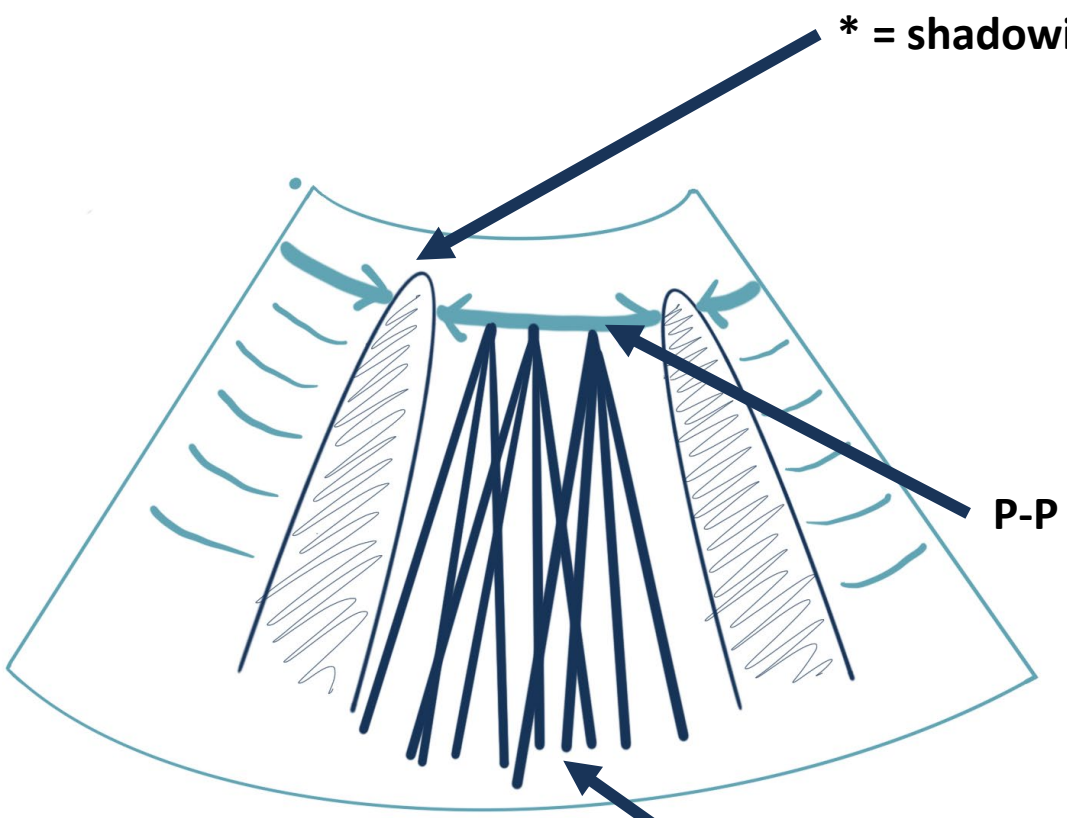

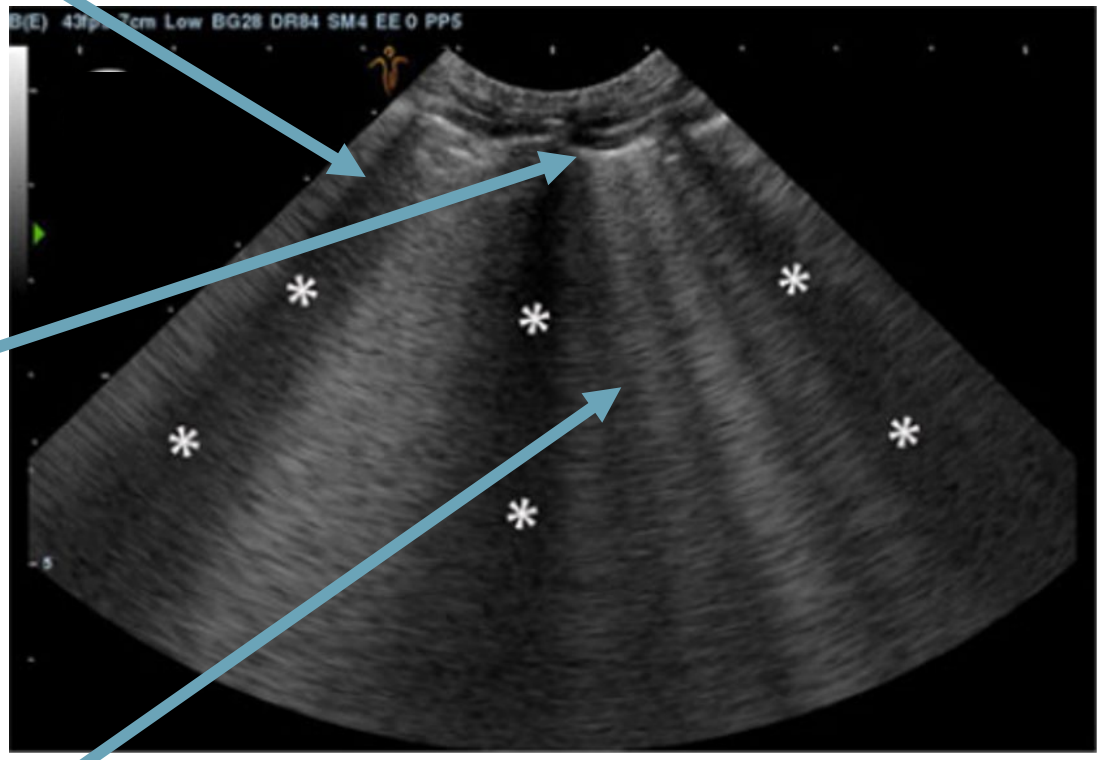

*** = shadowing from ribs**

P-P LINE

B-lines: WET lung

Ward, 2018

MedVet

B-lines
= WET lung

- Hyperechoic **vertical** lines
- Extend from P-P line to the far field
- Move to-and-fro with respiration
- **Obliterate A-lines**

Lungs – Linear Probe

Hyperechoic sliding line = pulmonary–pleural interface (PPI) - where the parietal and visceral pleura slide across one another

B-Lines = WET lung

A-Lines = DRY lung

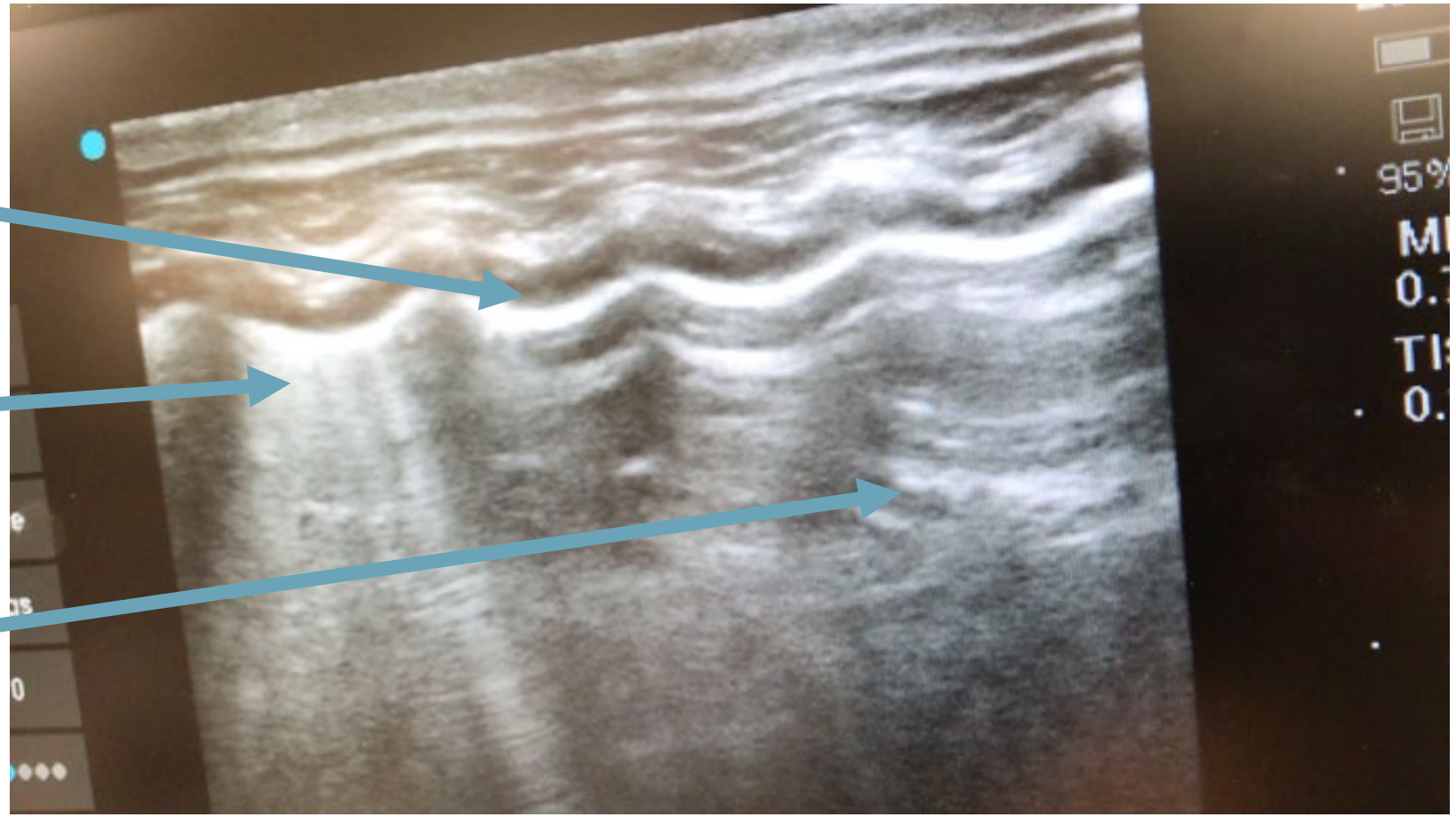

MedVet





Pleural / Pericardial Space

Curvilinear Probe

MedVet
Leading Specialty Healthcare for Pets

Pleural space

Pleural Effusion

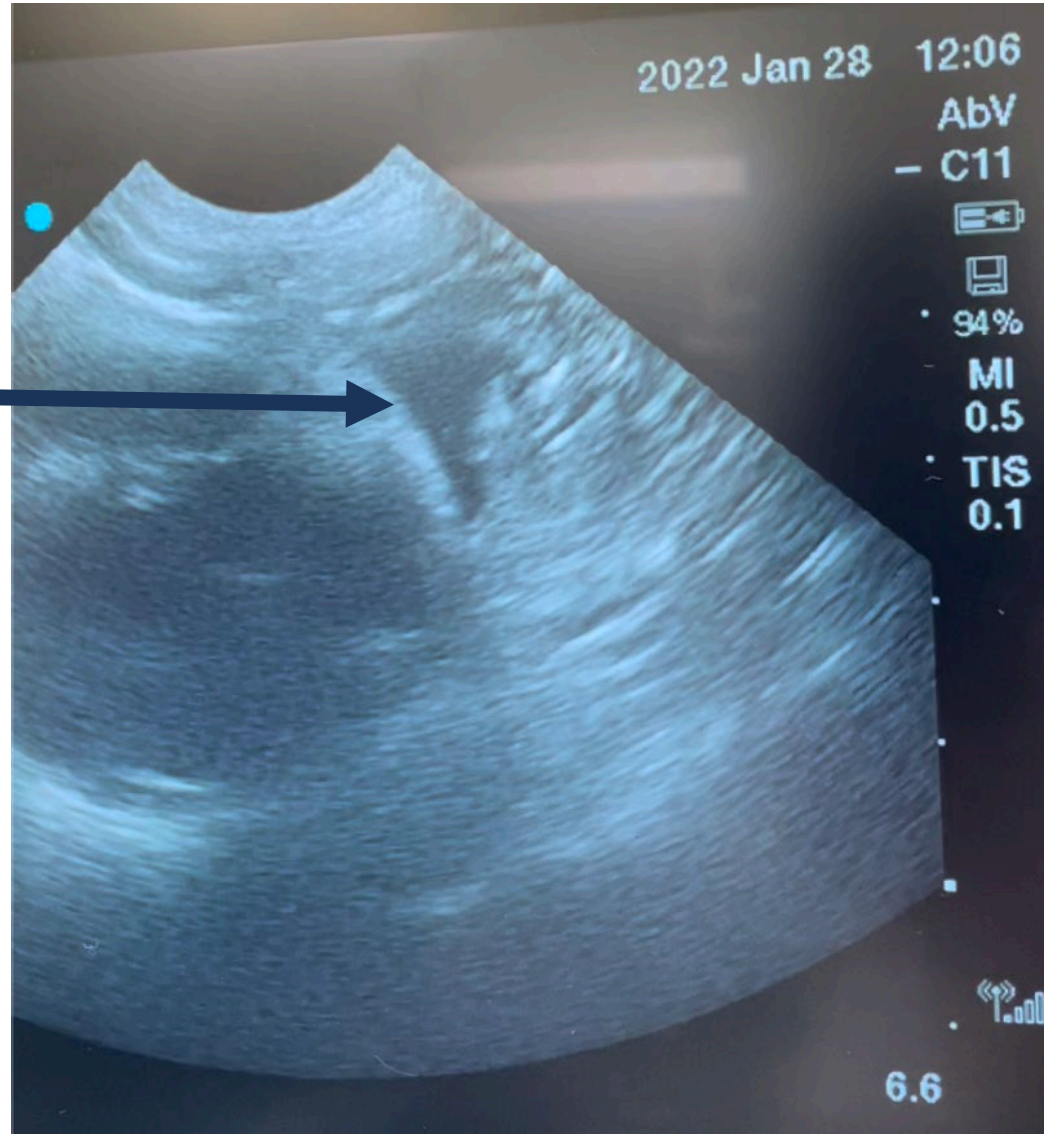

MEDVET

Pericardial Effusion?

Hypoechoic region around heart = pericardial effusion

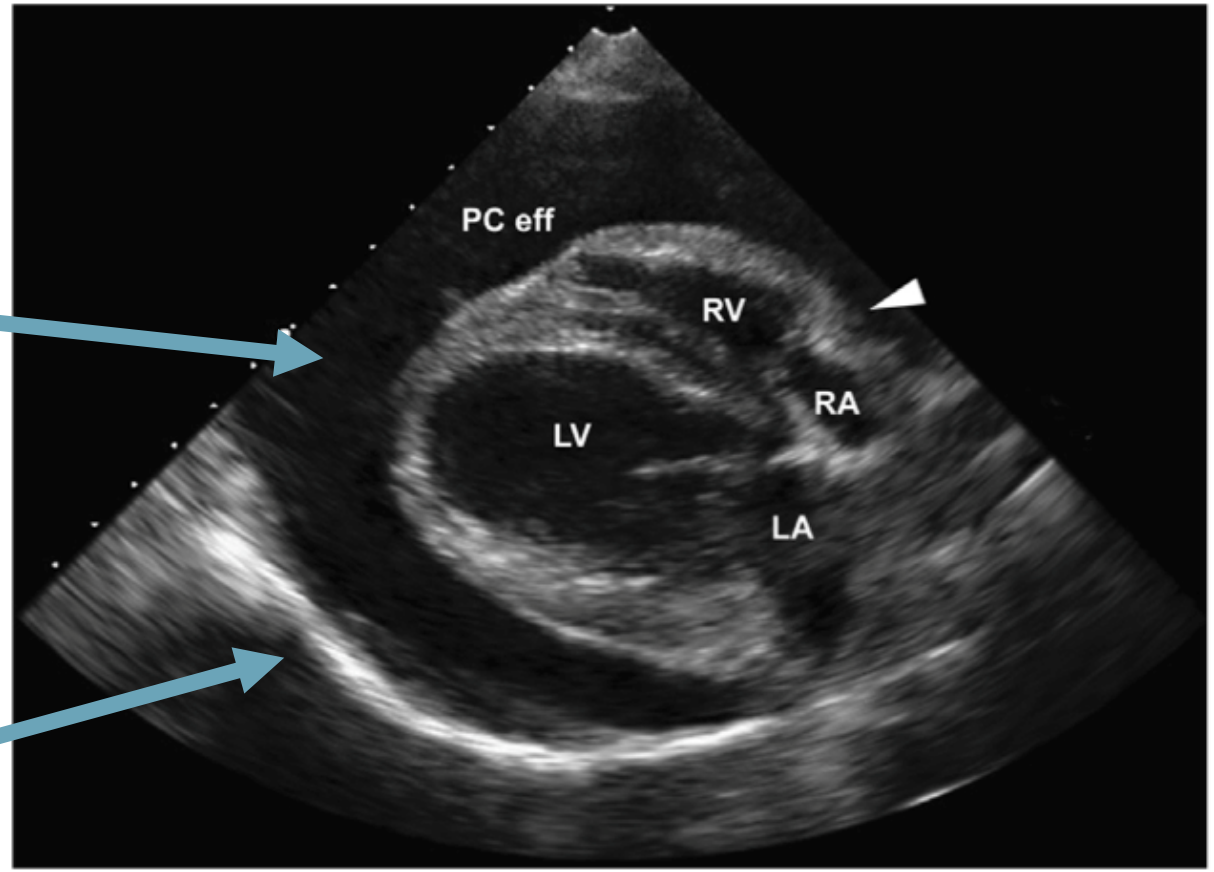

Hyperechoic structure = pericardium

Pericardial Effusion in a CAT

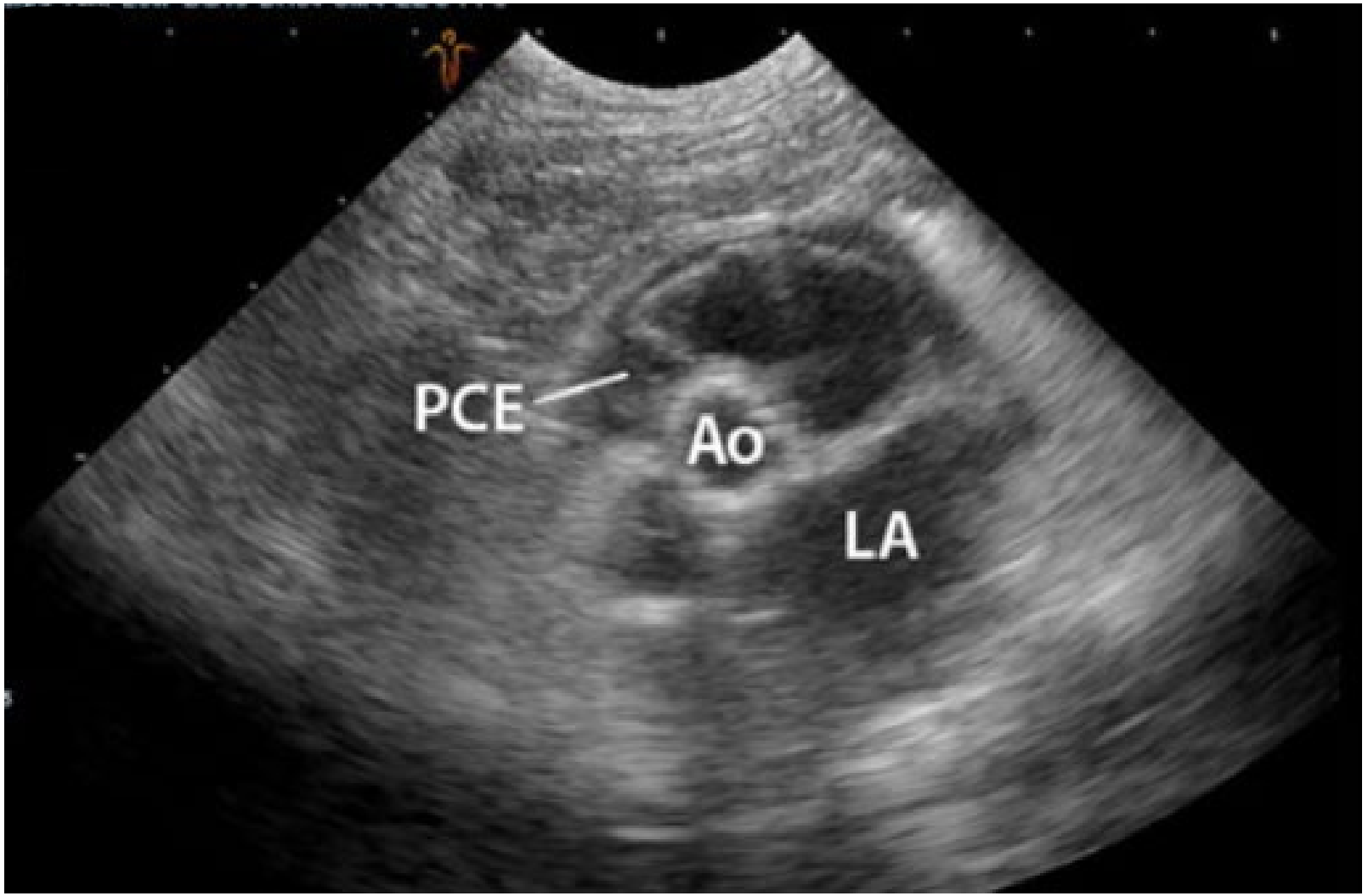

Ward, 2018.

MEDVET

What does the literature tell us?

MEDVET
Leading Specialty Healthcare for Pets

Feline heart disease can be difficult to diagnose in the ER



Journal of Veterinary Cardiology (2015) 17, S244—S257



Journal of Veterinary Cardiology
ESVC

www.elsevier.com/locate/jvc

Cardiomyopathy prevalence in 780 apparently healthy cats in rehoming centres (the CatScan study)

Jessie Rose Payne, BVetMed, PhD ,
David Charles Brodbelt, MA, VetMB, PhD ,
Virginia Luis Fuentes, MA, VetMB, PhD*

Clinical Science and Services, Royal Veterinary College, Hawkshead Lane, North Mymms, Hatfield, Hertfordshire, AL9 7TA, United Kingdom

MEDVET

Almost 20% of cats with HCM do NOT have a heart murmur

Payne, 2015.

MEDVET

Received: 25 August 2020 | Accepted: 30 April 2021

DOI: 10.1111/jvim.16156

STANDARD ARTICLE

Journal of Veterinary Internal Medicine
Open Access
ACVIM
American College of Veterinary Internal Medicine

Point-of-care N-terminal pro B-type natriuretic peptide assay to screen apparently healthy cats for cardiac disease in general practice

Ta-Li Lu[1] | Etienne Côté[2] | Yu-Wen Kuo[1] | Hao-Han Wu[1] | Wen-Yen Wang[1] | Yong-Wei Hung[1]

Lu, T. L., Côté, E., Kuo, Y. W., Wu, H. H., Wang, W. Y., & Hung, Y. W. (2021). Point-of-care N-terminal pro B-type natriuretic peptide assay to screen apparently healthy cats for cardiac disease in general practice. *Journal of Veterinary Internal Medicine*, *35*(4), 1663–1672.

MedVet

NT-proBNP: Point of Care screening test

NOT an effective *screening test* for cardiac disease in apparently healthy cats

NT-proBNP performance is improved if it is used **only** in cats that have a **heart murmur**

Lu, 2021.

POCUS

can help us separate heart disease from other causes of respiratory distress



MedVet

Journal of Veterinary Cardiology (2019) 24, 36–47



ELSEVIER

Journal of Veterinary Cardiology
ESVC

www.elsevier.com/locate/jvc

Left atrial size and volume in cats with primary cardiomyopathy with and without congestive heart failure☆

L. Duler, DVM, K.F. Scollan, DVM*, N.L. LeBlanc, DVM, MS

Department of Clinical Sciences, Carlson College of Veterinary Medicine, Oregon State University, Corvallis, OR, 97331, USA

Duler, L., K. F. Scollan, and N. L. LeBlanc. "Left Atrial Size and Volume in Cats with Primary Cardiomyopathy with and without Congestive Heart Failure." *Journal of Veterinary Cardiology* 24 (2019): 36–47.

MEDVET

The left atrium in cats with CHF
is significantly larger
than healthy cats and cats with cardiomyopathy

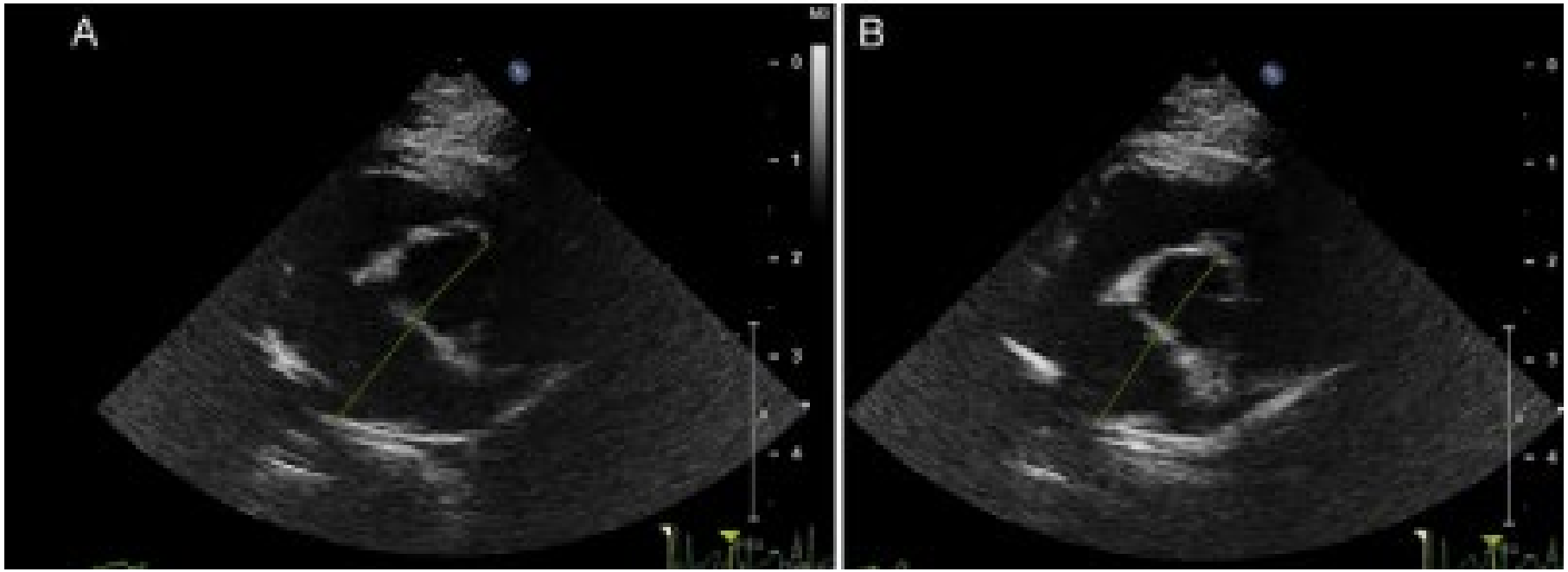

Duler, 2019.

MedVet

JOURNAL OF
Veterinary Emergency
AND Critical Care

Original Study

Journal of Veterinary Emergency and Critical Care **27**(5) 2017, pp 499–505
doi: 10.1111/vec.12637

Frequency and number of B-lines using a regionally based lung ultrasound examination in cats with radiographically normal lungs compared to cats with left-sided congestive heart failure

Gregory R. Lisciandro, DVM, DABVP, DACVECC; Robert M. Fulton, DVM;
Geoffrey T. Fosgate, DVM, PhD, DACVPM and Kelly A. Mann, DVM, DACVR

Lisciandro, Gregory R., Robert M. Fulton, Geoffrey T. Fosgate, and Kelly A. Mann. "Frequency and Number of B-Lines Using a Regionally Based Lung Ultrasound Examination in Cats with Radiographically Normal Lungs Compared to Cats with Left-Sided Congestive Heart Failure." *Journal of Veterinary Emergency and Critical Care* 27, no. 5 (2017): 499–505.

MEDVET

Cats with **CHF**
have **TNTC B-lines**
compared to normal cats
(who may have 0-2 B-lines identified)

Journal of Veterinary Internal Medicine
Open Access
ACVIM
American College of Veterinary Internal Medicine

STANDARD ARTICLE

Evaluation of point-of-care thoracic ultrasound and NT-proBNP for the diagnosis of congestive heart failure in cats with respiratory distress

Jessica L. Ward[1] | Gregory R. Lisciandro[2] | Wendy A. Ware[1] | Austin K. Viall[3] | Brent D. Aona[4] | Kari A. Kurtz[4] | Yamir Reina-Doreste[4] | Teresa C. DeFrancesco[4]

Ward, Jessica L., Gregory R. Lisciandro, Wendy A. Ware, Austin K. Viall, Brent D. Aona, Kari A. Kurtz, Yamir Reina-Doreste, and Teresa C. DeFrancesco. "Evaluation of Point-of-Care Thoracic Ultrasound and NT-ProBNP for the Diagnosis of Congestive Heart Failure in Cats with Respiratory Distress." *Journal of Veterinary Internal Medicine* 32, no. 5 (2018): 1530–40.

MedVet

POCUS in 51 cats *in respiratory distress*

Presence of B-lines and >1 pulmonary sites with B-lines: consistent with CHF

LA:Ao *subjectively enlarged* (> 2) consistent with CHF

Pericardial effusion:
100% specific for CHF (60% sensitive)

Abnormal proBNP– ***not*** significantly correlated with CHF

STANDARD ARTICLE

Journal of Veterinary Internal Medicine
Open Access

ACVIM
American College of Veterinary Internal Medicine

The use of focused cardiac ultrasound to screen for occult heart disease in asymptomatic cats

Kerry A. Loughran[1,2] | John E. Rush[1] | Elizabeth A. Rozanski[1] |
Mark A. Oyama[2] | Éva Larouche-Lebel[2] | Marc S. Kraus[2]

Loughran, Kerry A., John E. Rush, Elizabeth A. Rozanski, Mark A. Oyama, Éva Larouche-Lebel, and Marc S. Kraus. "The Use of Focused Cardiac Ultrasound to Screen for Occult Heart Disease in Asymptomatic Cats." *Journal of Veterinary Internal Medicine*, no. September 2018 (2019): 1–10.

MEDVET

Accuracy in Dx HCM

40%	PE and ECG
60%	After POCUS

Loughran, 2019.

MedVet

Back to Rascal…

MedVet
Leading Specialty Healthcare for Pets





Diffuse B-Lines

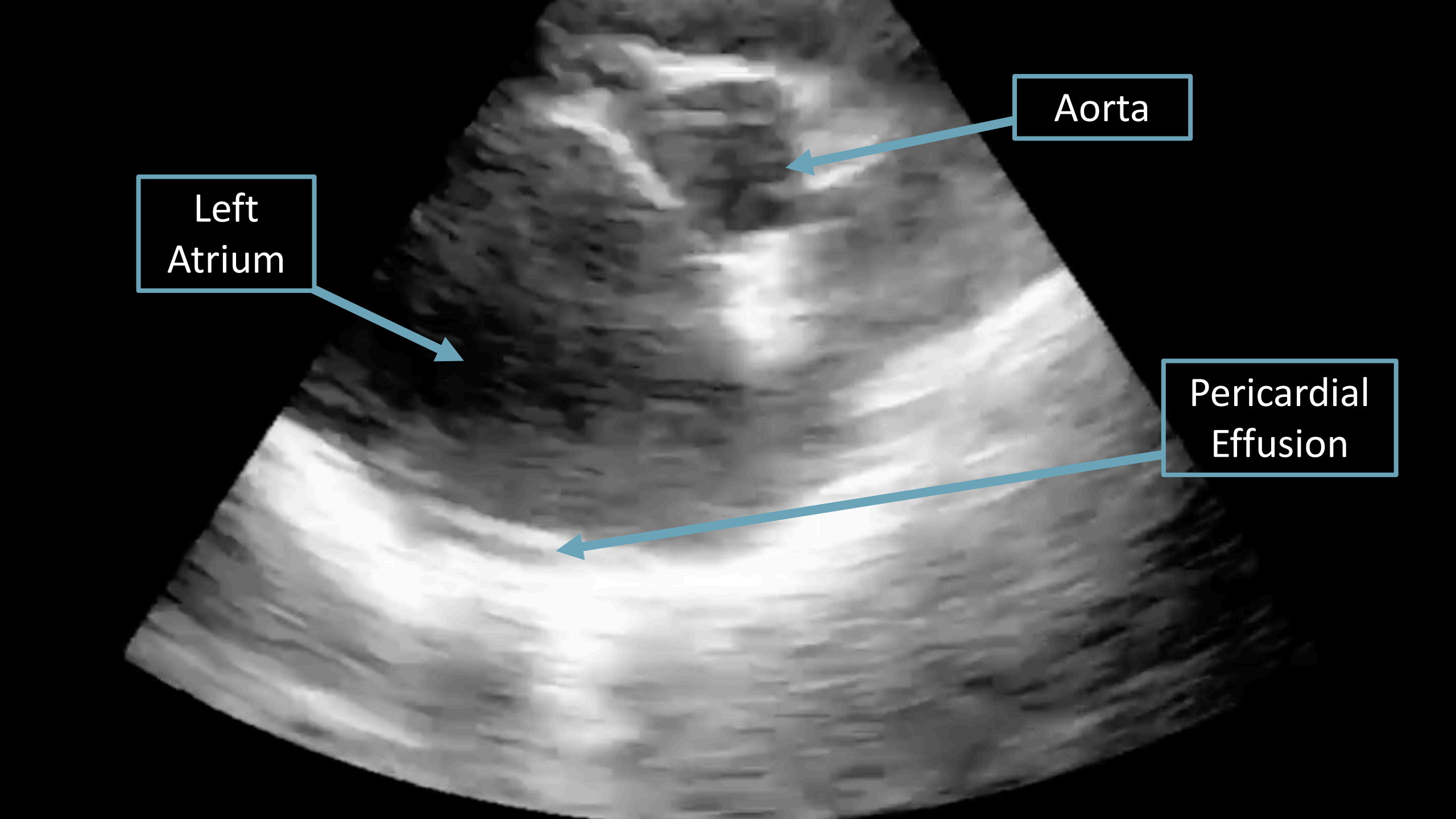
Aorta
Left Atrium
Pericardial Effusion

Rascal POCUS Findings:

- Diffuse B-lines
- Pleural Effusion
- Subjectively Thick LV
- Scant Pericardial Effusion
- LA:Ao > 2

Rascal Diagnosis

Congestive Heart Failure





BTBL:

Point of Care Ultrasound

is an effective modality for diagnosing feline CHF in both an ER and GP setting



Questions?

Contact: Andrew.Taylor@medvet.com

References

- Boysen, Søren R., and Gregory R. Lisciandro. “The Use of Ultrasound for Dogs and Cats in the Emergency Room AFAST and TFAST.” *Veterinary Clinics of North America - Small Animal Practice* 43, no. 4 (2013): 773–97.
- Côté, Etienne. “Feline Congestive Heart Failure: Current Diagnosis and Management.” *Veterinary Clinics of North America - Small Animal Practice* 47, no. 5 (2017): 1055–64.
- DeFrancesco, Teresa C. “Management of Cardiac Emergencies in Small Animals.” *Veterinary Clinics of North America - Small Animal Practice* 43, no. 4 (2013): 817–42.
- Duler, L., K. F. Scollan, and N. L. LeBlanc. “Left Atrial Size and Volume in Cats with Primary Cardiomyopathy with and without Congestive Heart Failure.” *Journal of Veterinary Cardiology* 24 (2019): 36–47.
- Hoskins, J. D. “Feline Respiratory Diseases.” *Veterinary Clinics of North America - Small Animal Practice* 29, no. 4 (1999): 945–58.
- Lichtenstein, Daniel A., and Gilbert A. Mezière. “Relevance of Lung Ultrasound in the Diagnosis of Acute Respiratory Failure the BLUE Protocol.” *Chest* 134, no. 1 (2008): 117–25.
- Lisciandro, Gregory R. “Abdominal and Thoracic Focused Assessment with Sonography for Trauma, Triage, and Monitoring in Small Animals.” *Journal of Veterinary Emergency and Critical Care* 21, no. 2 (2011): 104–22.
- Lisciandro, Gregory R., Robert M. Fulton, Geoffrey T. Fosgate, and Kelly A. Mann. “Frequency and Number of B-Lines Using a Regionally Based Lung Ultrasound Examination in Cats with Radiographically Normal Lungs Compared to Cats with Left-Sided Congestive Heart Failure.” *Journal of Veterinary Emergency and Critical Care* 27, no. 5 (2017): 499–505.
- Lisciandro, Gregory R. “The Vet BLUE Lung Scan.” *Focused Ultrasound Techniques for the Small Animal Practitioner*, edited by Gregory R. Lisciandro, Wiley-Blackwell, 2014, pp. 166–188.

References

- Loughran, Kerry A., John E. Rush, Elizabeth A. Rozanski, Mark A. Oyama, Éva Larouche-Lebel, and Marc S. Kraus. “The Use of Focused Cardiac Ultrasound to Screen for Occult Heart Disease in Asymptomatic Cats.” *Journal of Veterinary Internal Medicine*, no. September 2018 (2019): 1–10.
- Lu, T. L., Côté, E., Kuo, Y. W., Wu, H. H., Wang, W. Y., & Hung, Y. W. (2021). Point-of-care N-terminal pro B-type natriuretic peptide assay to screen apparently healthy cats for cardiac disease in general practice. *Journal of Veterinary Internal Medicine*, *35*(4), 1663–1672.
- Payne, Jessie Rose, David Charles Brodbelt, and Virginia Luis Fuentes. “Cardiomyopathy Prevalence in 780 Apparently Healthy Cats in Rehoming Centres (the CatScan Study).” *Journal of Veterinary Cardiology* 17 (2015): S244–57.
- Reinero, Carol R. “Feline Asthma.” *Veterinary Allergy*, edited by Chiara Noli et al, John Wiley & Sons, Inc, 2013, pp. 239–45.
- Sumner, Catherine, and Elizabeth Rozanski. “Management of Respiratory Emergencies in Small Animals.” *Veterinary Clinics of North America - Small Animal Practice* 43, no. 4 (2013): 799–815.
- Trzil, Julie E., and Carol R. Reinero. “Update on Feline Asthma.” *Veterinary Clinics of North America - Small Animal Practice* 44, no. 1 (2014): 91–105.
- Volpicelli, Giovanni, Mahmoud Elbarbary, Michael Blaivas, Daniel A. Lichtenstein, Gebhard Mathis, Andrew W. Kirkpatrick, Lawrence Melniker, et al. “International Evidence-Based Recommendations for Point-of-Care Lung Ultrasound.” *Intensive Care Medicine* 38, no. 4 (2012): 577–91.

References

- Ward, Jessica L., Gregory R. Lisciandro, and Teresa C. DeFrancesco. “Distribution of Alveolar-Interstitial Syndrome in Dogs and Cats with Respiratory Distress as Assessed by Lung Ultrasound versus Thoracic Radiographs.” *Journal of Veterinary Emergency and Critical Care* 28, no. 5 (2018): 415–28.
- Ward, Jessica L., Gregory R. Lisciandro, Wendy A. Ware, Austin K. Viall, Brent D. Aona, Kari A. Kurtz, Yamir Reina-Doreste, and Teresa C. DeFrancesco. “Evaluation of Point-of-Care Thoracic Ultrasound and NT-ProBNP for the Diagnosis of Congestive Heart Failure in Cats with Respiratory Distress.” *Journal of Veterinary Internal Medicine* 32, no. 5 (2018): 1530–40.