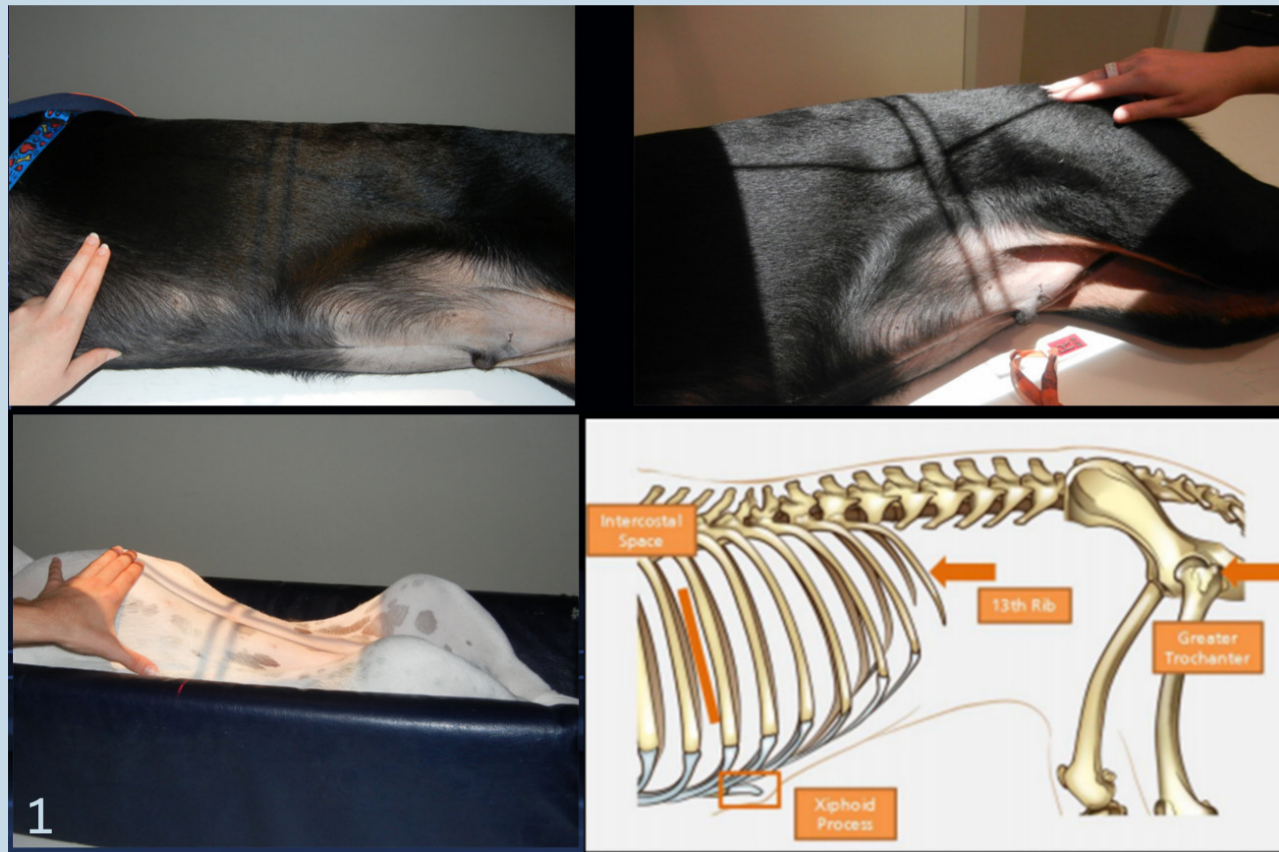


# Technical Tips

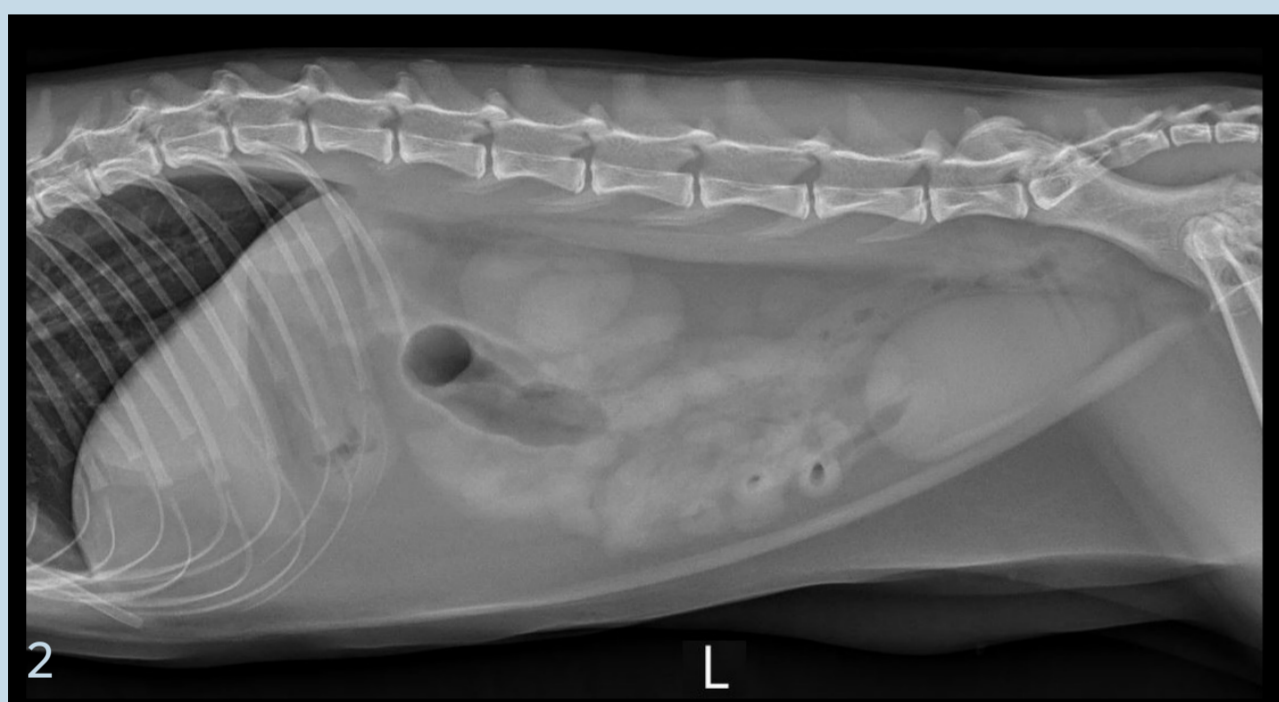
## Radiography: Abdomen



### Include All Anatomy

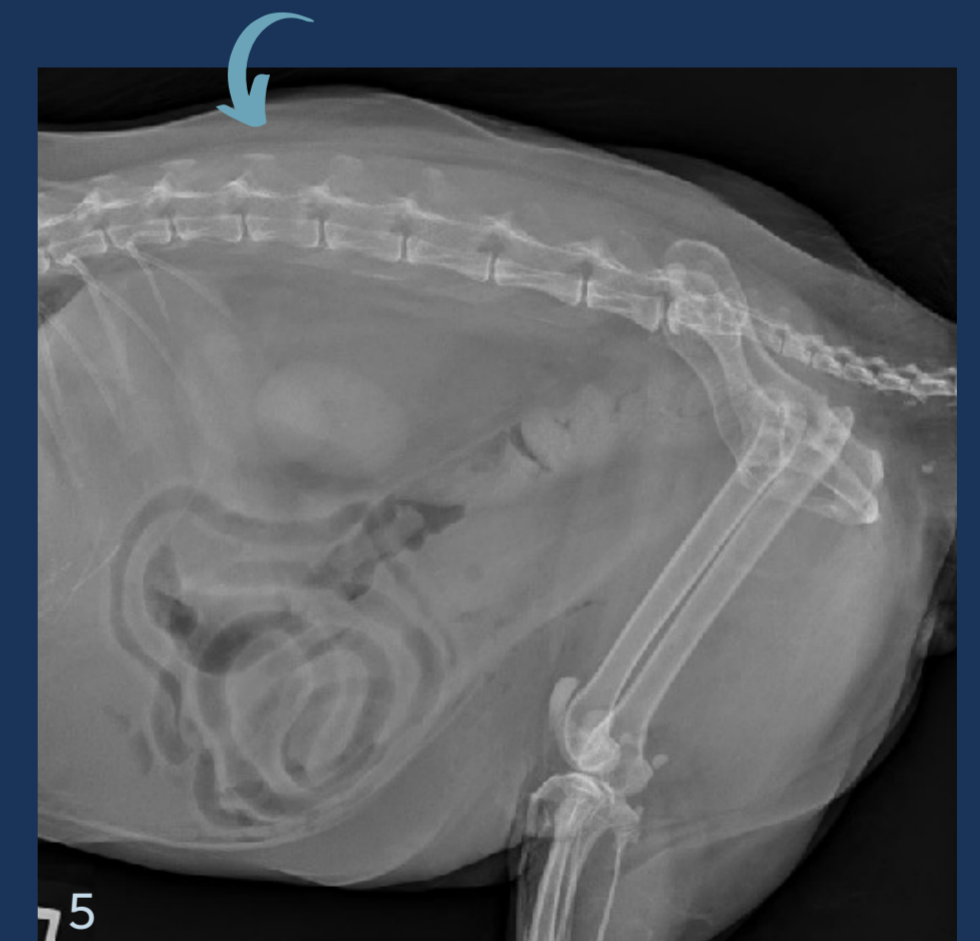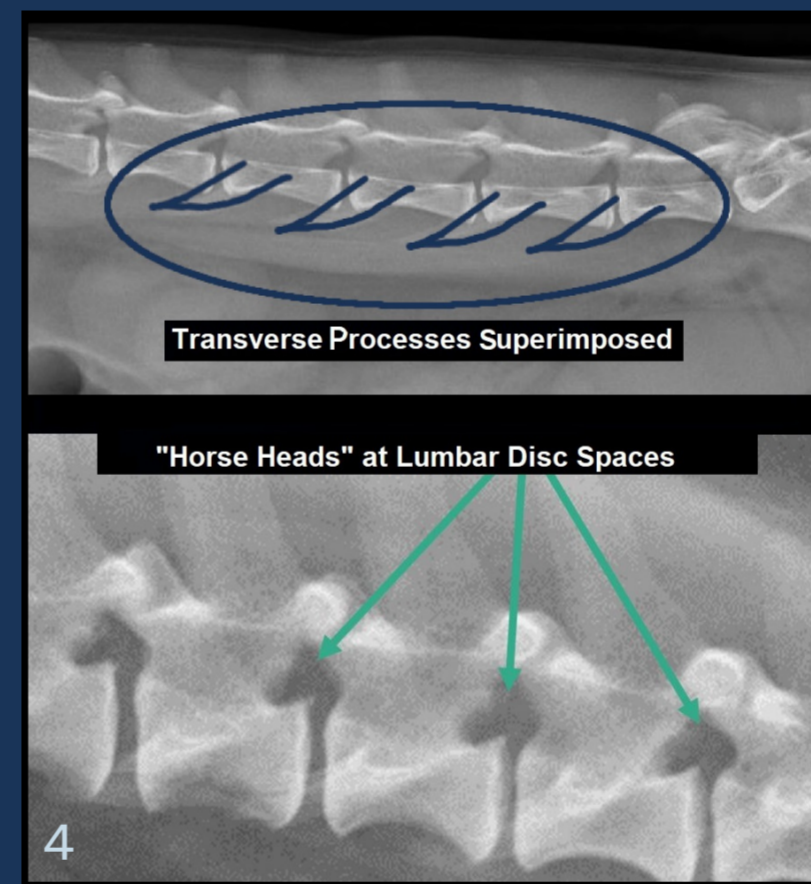
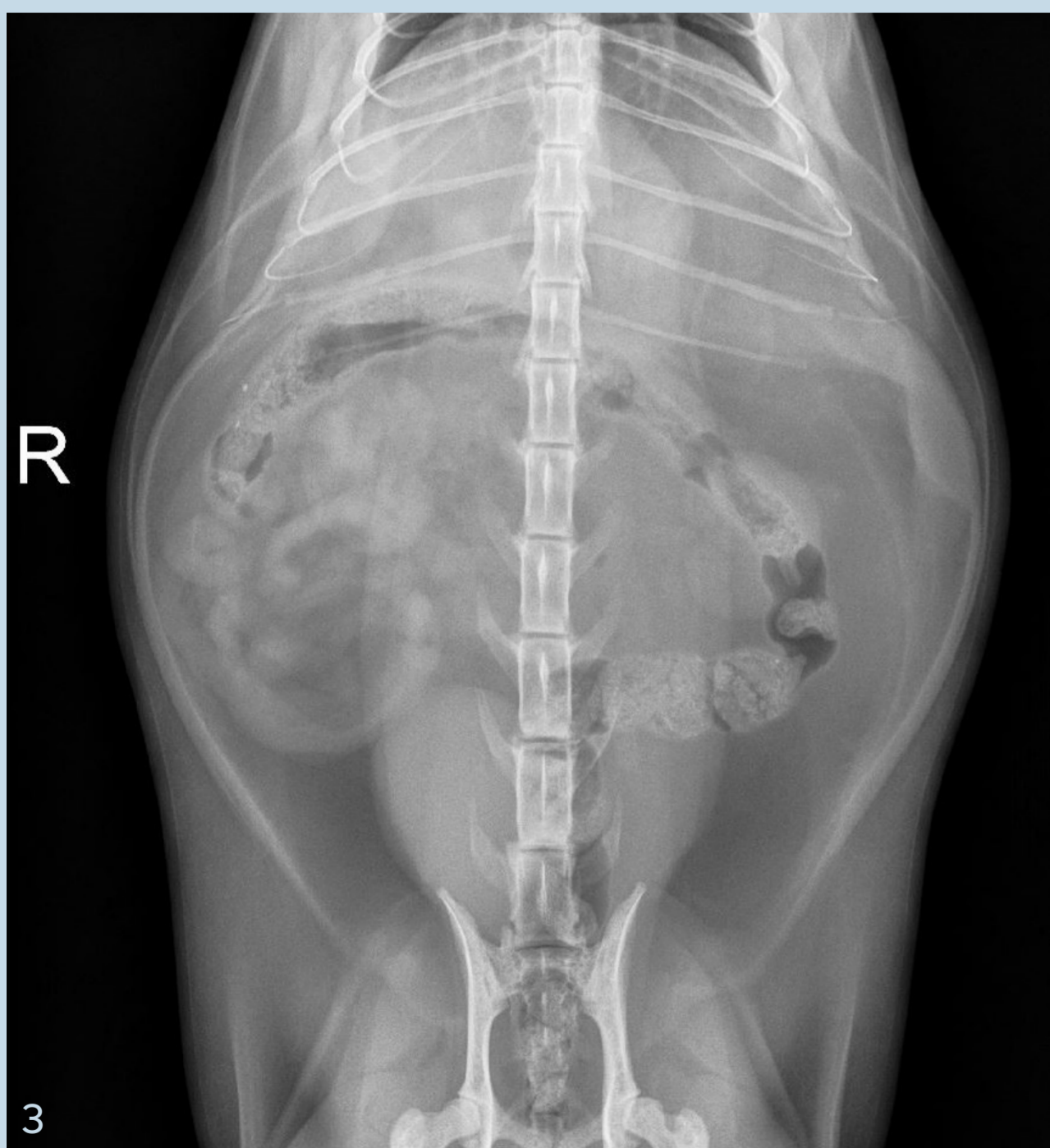#### Palpate Landmarks:

- Center about 13th rib
- Xiphoid + 4 fingers cranial for entire liver
- Dorsal spinous processes and ventral sternum
- Greater trochanter of hip



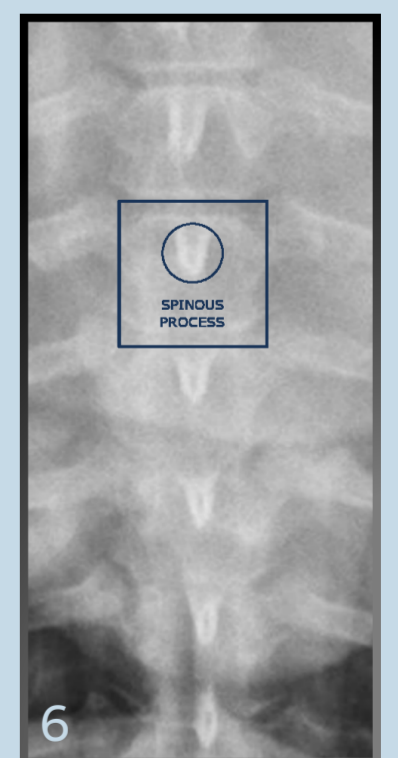
### Urinary History

- Include all caudal soft tissue to visualize urethra
- If male, add flexed lateral view



### VD View

- Avoid rotation
- Center the spinal column



**All Views: Take on Expiration**

Images courtesy of:  
Danielle Mauragis, CVT, Radiology, University of Florida, 2015. Images 1, 4 and 6.  
MedVet (2021). Images 2, 3, and 5.